

Cadaveric Study of Hip Joint in South Maharashtra

Swapnilkumar L. Sarada*, P. R. Chavan**, P. R. Kulkarni***, M. M. Baig****, M. S. Selukar*****

Abstract

Introduction: There is very less study on the cadaveric hip joint. There is some sort of difference seen in dry bone & cadaveric [wet] bone. Cadaveric studies on dimensions of articulating surfaces of hip joint have need to be much studied because they correlate well with surgical anatomy needed for operative procedures. **Materials & Methods:** 42 cadaveric hip joints with soft tissue in situ from various medical colleges in south Maharashtra region were studied. Dimensions of Acetabulum & Femoral head were obtained with Vernier scale. **Conclusion:** The depth of acetabulum was greater in males than females on both right and left side which was statically significant. Remaining parameters that is diameter of acetabulum, vertical and horizontal diameter of femoral head on both sides were greater in males than females but statistically insignificant.

Though in present study left hip joint parameters were greater than the right, yet they were statistically insignificant. Present study helps for prosthetics, orthopaedicians & forensic experts as it gives dimensions of the acetabulum & femoral head in present era.

Keywords: Cadaver; Acetabulum; Hip Joint; Vernier Scale.

Introduction

The hip joint is a multi-axial ball and socket type of synovial joint. The articular surfaces are reciprocally curved but neither coextensive nor completely congruent. Acetabular depth is increased by acetabular labrum a fibro-cartilaginous rim attached to the acetabular margin. This deepens the acetabular cup, bridges and the acetabular notch. The diameter of the acetabular cavity is constricted by the labral rim, which embraces the femoral head. Cadaveric studies on dimensions of articulating surfaces of hip joint have need to be much studied because they correlate well with surgical anatomy needed for operative procedures.

Author's Affiliation: *Tutor ***Professor & HOD *****Associate Professor, Department of Anatomy, Government Medical College, Latur. **Assistant Professor, Department of Anatomy, Government Medical College, Aurangabad. ****Professor & HOD, Department of Anatomy, Government Medical College, Solapur.

Corresponding Author: Swapnilkumar L. Sarada, Tutor, Dept. of Anatomy, Government Medical College, Latur-413512, Maharashtra, India.
E-mail: drswapnilsarda@yahoo.com

Objectives

The present study was undertaken to study & compare male & female articulating surfaces of hip joint in cadavers which will be of great help for surgical / prosthetic procedures on hip joint. No such study in south Maharashtra is available since long time. Any deviation of these dimensions from normal has strong association with development of various kinds of pathologies of hip joint.

Materials & Methods

This study was conducted in the department of Anatomy, Govt. Medical College Latur & MIMSR Medical College Latur.

Forty two [42] cadaveric hip joints belonging to the age group of 30 to 70 year of both sexes were dissected.

Inclusion Criteria

The hip joints were considered normal when (a) the acetabulum was hemispherical & cartilage

lining it was smooth & lunate shaped, ending abruptly at the inner margin framing the acetabular fossa as unbroken line. Outer edge of the cartilage labrum blended without any distinctive demarcation, acetabular fossa was filled with fibro-fatty tissue with a smooth surface. (b) The articular cartilage of femoral head was smooth & of uniform appearance till the margin where it disappeared with no evidence of marginal ossification.

Exclusion Criteria

The hip joints having damaged articular surfaces, irregularity in cartilage & prosthesis. Various dimensions of the acetabulum & head of the femur of forty two joints [32 male, 10 female; 21 right, 21 left] were measured in mm as following.

Depth of acetabulum: Depth of acetabulum was measured in mm using vernier scale from the centre of acetabulum to the metallic strip which was placed across the diameter of the acetabulum.

Diameter of acetabulum: Maximum transverse diameter of the acetabulum was measured using vernier scale.

Vertical diameter of femoral head: The straight distance between most superior to the most inferior point of femoral head was measured by vernier scale.

Horizontal diameter of femoral head: The straight distance between most anterior to the most posterior point of femoral head was measured by vernier scale.

Fig. 1: Showing measurement of depth of acetabulum

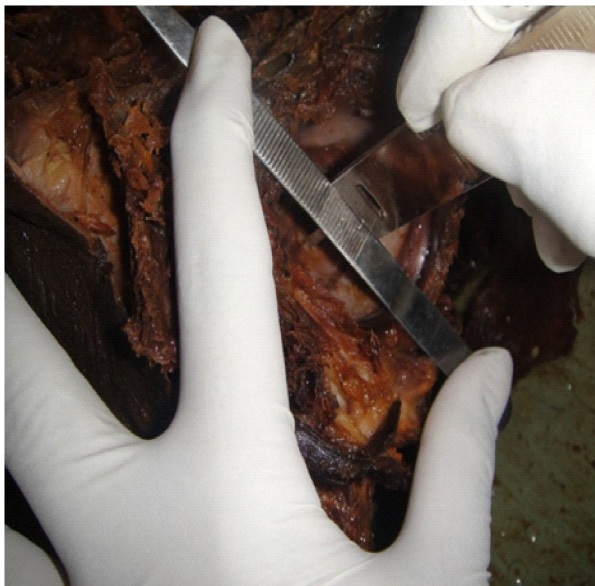

Fig. 2: Showing measurement of diameter of acetabulum

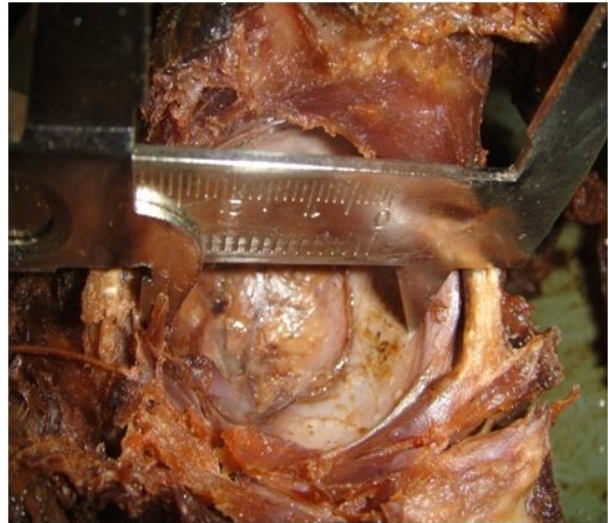

Fig. 3: Showing measurement of vertical diameter of femoral head

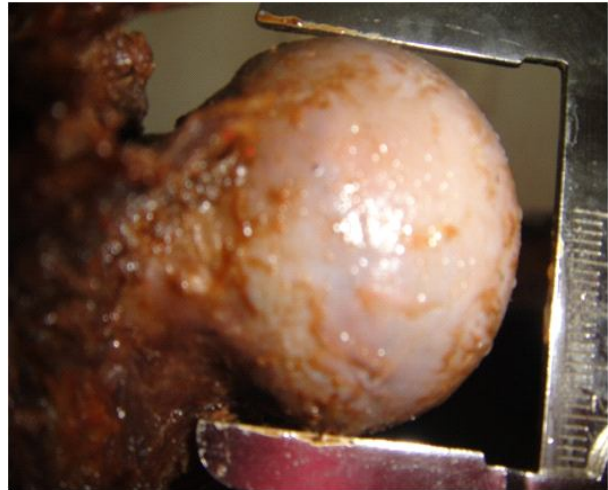
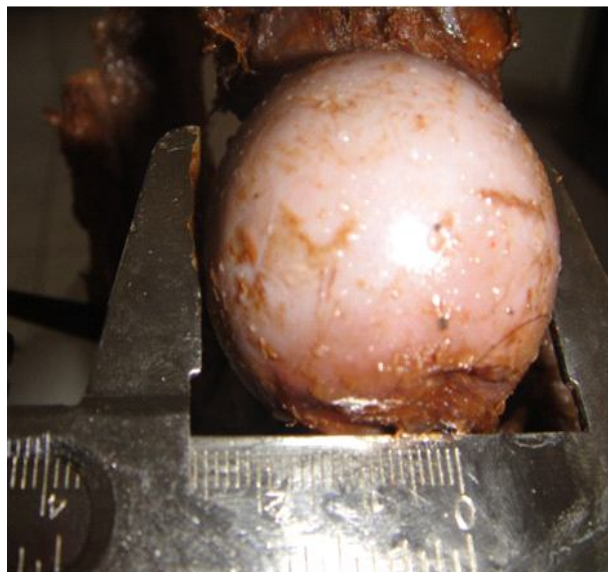


Fig. 4: Showing measurement of horizontal diameter of femoral head



Variation was avoided by measuring each parameter three times & mean of reading obtained was recorded.

Observations & Results

Forty two (42) hip joints were dissected & grossly inspected.

Data obtained was analyzed in the following manner.

- Measurements of right side in males were compared with right side in females.
- Measurements of left side in males were compared with left side in females.
- Measurements of right side were compared with left side in males.

Table 1: Depth of acetabulum [n= 42; right 21, left 21]

	Male (n= 32)		Female (n=10)	
	Right=16	Left=16	Right=05	Left=05
Range	21.00-32.10	22.50-33.00	23.00-26.00	24.5-27.00
Mean	28.10	29.12	24.80	26.10
Standard Deviation	3.31	3.27	1.30	0.96
Standard Error of Mean	0.82	0.81	0.58	0.43
	[Right p <0.05, Left p >0.05]		[Male p >0.05 , Female p >0.05]	

It was observed that the depth of acetabulum was greater in males than in females both on right & left side [table 1], on right side the difference being statistically significant [Right p <0.05, Left p >0.05].

The depth of left acetabulum was greater than that of the right side in both sexes but the difference was statistically insignificant [Male p >0.05, Female p >0.05].

Table 2: Diameter of acetabulum [n= 42; right 21, left 21]

	Male (n= 32)		Female (n=10)	
	Right=16	Left=16	Right=05	Left=05
Range	38.20-50.20	39.70-51.30	39.00-46.00	41.00-46.80
Mean	44.33	45.18	42.60	43.84
Standard Deviation	3.44	3.39	2.70	2.34
Standard Error of Mean	0.86	0.84	1.21	1.04
	[Right p >0.05, Left p >0.05]		[Male p >0.05, Female p >0.05]	

It was noticed that the diameter of acetabulum was greater in males than in females both on right & left side [table 2] but statistically insignificant [Right p >0.05, Left p >0.05].

In both the genders left acetabulum had greater diameter than that of right side but of no statistical significance [Male p >0.05, Female p >0.05].

Table 3: Vertical diameter of femoral head [n= 42; right 21 left 21]

	Male (n= 32)		Female (n=10)	
	Right=16	Left=16	Right=05	Left=05
Range	37.40-49.10	38.50-50.00	37.80-45.00	40.30-45.70
Mean	43.16	44.07	41.32	42.72
Standard Deviation	3.37	3.27	3.27	2.26
Standard Error of Mean	0.84	0.81	1.32	1.01
	[Right p >0.05 Left p >0.05].		[Male p >0.05 Female p >0.05]	

It was observed that the vertical diameter of femoral head was greater in males than in females both on right & left sides [table 3] but was statistically insignificant [Right p >0.05, Left p >0.05].

In both the genders, the vertical diameter was more on left side than right side though the difference was statistically insignificant [Male p >0.05, Female p >0.05].

Table 4: Horizontal diameter of femoral head [n= 42; right 21, left 21]

	Male (n= 32)		Female (n=10)	
	Right=16	Left=16	Right=05	Left=05
Range	37.50-49.30	38.60-50.70	37.80-45.10	40.40-45.80
Mean	43.44	44.31	41.40	42.84
Standard Deviation	3.35	3.34	2.98	2.27
Standard Error of Mean	0.83	0.83	1.33	1.01
	[Right p >0.05 Left p >0.05]		[Male p >0.05 Female p >0.05]	

It was noticed that the horizontal diameter of femoral head was greater in males than in females both on right & left sides [table 4] but was statistically insignificant [Right p >0.05, Left p >0.05].

In both the genders the horizontal diameter was more on left side than right side but the difference was statistically insignificant [Male p >0.05 Female p >0.05].

- (d) Measurements of right Side were compared with left side in females.

Studying cadaveric hip joint is very important as various parameters are taken with soft tissue in situ.

Discussion

Hip joint is a multi-axial synovial joint of ball & socket type. The work of Menschik (1997) [1] shows that hip joint is more of Conchoid than a ball & socket type. Study of the anatomical parameters of the bony components of hip joint is very essential for the better understanding of etio-pathogenesis of diseases like osteoarthritis of hip joint. An abnormal joint is more prone to develop degenerative changes than anatomically normal joint. (Murry 1965) [2].

Dimensions of Acetabulum & femoral head will greatly help to prosthetists to construct suitable prosthesis as total hip replacement is a common surgery. Knowledge of average dimension of articulating surfaces of hip joint in both sexes will also help to forensic experts in case of disputed sex.

To the best of our knowledge not much study is available on these parameters of hip joints in south Maharashtra.

So this cadaveric study gives the average values of various parameters to near normal as would be encountered in the patients at operation table.

Mean depth of acetabulum in present study was in males on right & left side 28.10 mm & 29.12 mm respectively & in females on right & left side are 24.80 mm & 26.10 mm respectively. These findings are correlated with study done by Prasad et al (1996) [4], to Chauhan R. et al (2002) [5], Jayshree et al (2013) [6] as shown in table 5. Mean depth of acetabulum according to Mukhopadhaya & Barroah (1967) [3] on right & left sides are 24.7 mm & 24.5 mm respectively. Difference in their observations when compared with the present study exists as they included the dimensions of both the sexes while calculating mean. Also their study were on fresh specimens. In preserved materials the soft tissue shrinks & hence emergence of higher values in the present study.

Mean diameter of acetabulum in present study was in males on right & left side 44.33 mm & 45.18 mm respectively and in females on right and left side are

Table 5: Comparison table

No.	Studies		Depth of acetabulum in mm		Diameter of acetabulum in mm		Vertical Diameter of Femoral head in mm	
			Male	Female	Male	Female	Male	Female
01	Javedkar 1961	Right	-	-	-	-	45.26	40.37
		Left	-	-	-	--	-	-
02	Mukhopadhay 1967	Right	-	24.7	-	48.5	-	-
		Left	-	24.5	-	46.0	-	-
03	Prasad et al 1996	Right	28.00	27.09	45.22	40.65	44.31	39.74
		Left	28.51	26.73	45.39	40.21	44.76	39.42
04	Asla 1998	Right	-	-	-	-	54.23	47.14
		Left	-	-	-	-	54.08	46.83
05	Chauhan R. et al 2002	Right	27.49	24.68	47.10	44.38	45.44	43.87
		Left	28.18	25.7	47.48	46.00	45.84	44.67
06	Jayshree et al 2013	Right	29.97	27.45	45.42	41.77	44.84	41.12
		left	30.37	27.58	45.07	41.98	44.53	41.07
07	Present study	Right	28.1	24.8	44.33	42.6	43.16	41.32
		Left	29.12	26.1	45.18	43.84	44.07	42.72

42.6 mm & 43.84 mm respectively which is nearly same as seen in study done by Prasad et al (1996) [4], to Chauhan R. et al (2002) [5], Jayshree et al (2013) [6] as shown in table 5.

Mean vertical diameter of femoral head in present study was in males on right & left side 43.16 mm & 44.07 mm respectively and in females on right & left side was 41.32mm & 42.72mm respectively which is correlated with study done by Prasad et al (1996) [4], to Chauhan R. et al (2002) [5], Jayshree et al (2013) [6] as shown in table 5.

It was noticed by Javedkar (1961) [7] that mean vertical diameter in males was 45.26 mm and in females is 40.37 mm. Cartilage adds 3 mm to the diameter (Javedkar) [7]. Mean vertical diameter of the head of the femur on right & left side in male was 54.23 mm & 54.08 mm respectively and in females it is 47.14 mm & 46.83 mm of Nigerians femur. (Asla, Propandro 1998) [8]. Study conducted by Isaac, Vettival, Prasad, Jeyasalan & Chandi (1997) [9] shows that short statured have smaller diameters of femoral head which can be easily understood when present work compared with study of Asla. Nigerians are taller than average Indians. So their femoral heads are bigger than that of Indians.

Mean horizontal diameter of femoral head in present study was in males on right & left side 43.44 mm & 44.31 mm respectively and in females on right and left side are 41.40mm & 42.84 mm respectively. No such study was found in relation with hip joint for comparison.

It was observed that average diameter of acetabulum is larger than average diameter of femoral head irrespective of the sex emphasizing upon the fact that femoral head is snugly fitted into the acetabulum. Due to this fact primary osteoarthritis of hip joint is uncommon in Indians.

Various parameters measured had higher values on left side than right side. Chibber & Singh (1970) [10], Dogra & Singh (1971) [11] noticed that left limb is dominant whether a person is right handed or left handed. More persons use left lower limb for weight bearing.

Conclusion

The depth of acetabulum was greater in males than females on both right and left side which was statically significant.

Remaining parameters that is diameter of acetabulum, vertical and horizontal diameter of

femoral head on both sides were greater in males than females but statistically insignificant.

Though in present study left hip joint parameters were greater than the right, yet they were statistically insignificant.

The present study gives valuable information about hip joint parameters which would greatly help surgeons, anthropologists & prosthetists to perform excellently in their respective specialities.

References

1. Menschik F. The hip joint as a conchoids shape. *Journal of Biomechanic*. 1997; 30(9): 971-73.
2. Murry R O. The etiology of primary osteoarthritis of the hip. *British Journal of Radiology*. 1965; 38: 810-24.
3. Mukhopadhyaya, B arroah. Osteoarthritis of hip in Indians. *Indian Journal of Orthopaedic*.1967; 1[1]: 55-62.
4. Prasad R, Vettival S, Jeyaseelan L, Isaac B, Chandi G . Reconstruction of femur length from makers of its proximal end. *Journal of clinical anatomy*.1996; 9: 28-33.
5. Chavan R, Paul S, Dhaon B K. Anatomical parameters of north Indian hip joints. *Journal of Anatomical society of india*. 2002; 51[1]: 39-42.
6. Jayshree P, Meenakshi B, Dipal A, Mehta C.A study of anatomical parameters of hip joint in cadavers and its clinical importance. *CIBTech Journal of Surgery*.2013; 2: 44-50.
7. Javedkar B S. A study of measurements of the femur with special references to sex. *Journal of Anatomical society of india*.1961; 10: 25-27.
8. Asla S A, Papandro B A. A comparative study of femoral head diameters & sex differentiation in Nigerians. *Acta Anatomica*.1998; 162: 232-37.
9. Issac, Vettival, Prasad, Jeyaseelan, Chandi. Prediction of the femoral neck shaft angle from the length of femoral neck. *Clinical Anatomy*, 1997; 10: 318-23.
10. Chhibber S R, Singh I. Assymetry in muscle weight and one side dominance in the human lower limbs. *Journal of Anatomy*. 1970; 106(3): 553-56.
11. Dogra S K, Singh I. Asymmetry in bone weight in the human lower limbs. *Anatomischer Anzeiger*. 1971; 128: 278- 80.